

Treatment of a Patient with an Impacted Transmigrant Mandibular Canine and a Palatally Impacted Maxillary Canine

Joe Rebellato, DDS^a; Brian Schabel^b

Abstract: Very few people have seen transmigrant mandibular canines and little has been presented in the literature about this rare phenomenon. In this case report, identification techniques and treatment options are presented along with the treatment results of a patient diagnosed with a transmigrant mandibular canine. This rare condition usually requires extraction of the involved tooth because orthodontic forces are seldom successful at erupting these teeth into their proper location. The treatment protocol for this patient involved a combination of orthodontic procedures, surgical extractions, gingivectomy and frenectomy, and implant replacement of the impacted transmigrant tooth. Through a collaborative effort of a team made up of an orthodontist, periodontist, prosthodontist, and oral surgeon, these techniques were used to achieve an excellent esthetic and functional outcome. (*Angle Orthod* 2003;73:328–336.)

Key Words: Transmigrant mandibular canines; Multidisciplinary care; Implant replacement; Root resorption; Ankylosis; Autotransplantation; Malposition; Impaction

INTRODUCTION

Impaction refers to a failure of a tooth to emerge into the dental arch, usually due either to space deficiencies or the presence of an entity blocking its path of eruption.¹ Although heredity has long ago been described as playing a role,² many times the etiology is unknown. Impacted teeth are commonly found in dental practice, and they pose a threat for the maintenance and continuity of dental health. Primarily because of their eruption pattern and sequence, canines are especially prone to impaction and the maxillary canines are affected 20× more frequently than mandibular canines.³

Transmigration⁴ refers to the physiological migration of an unerupted tooth across the midline in the absence of pathology or trauma. Thoma⁵ describes the transmigration of mandibular canines as a very rare phenomenon, and transmigration of maxillary canines across the midpalatal suture has not been observed.⁶ The etiology of transmigrant teeth is not known,² although it is thought to be the result of a malpositioning of the dental lamina during the embryonic stage of tooth development.⁶ Combining a recent study with an exhaustive compilation of earlier reports on trans-

migratory mandibular canines from 1952 to 1994, Joshi⁶ found that 89% were impacted, and 91% were unilateral. These teeth are generally asymptomatic⁷ and although the tooth is far from its original site, it maintains its nerve supply from the side which it came.⁸ Transmigrant teeth usually require clinical and radiographic examination to diagnose because they are usually found within the symphysis of the mandible. Clinical clues include overretention of the primary canine,⁹ proclination of the mandibular teeth, and an enlarged symphyseal area¹⁰ that grows to accommodate this malpositioned tooth. Panorex, occlusal, periapical, and submentovertex projections can be used to confirm the three-dimensional location of the transmigrated tooth because they are often found beneath the apices of the mandibular teeth, and located either buccally, lingually, or centrally.

History

The patient was a 12-year 11-month-old white female when she first presented for an orthodontic consultation. The family was self-referred and presented for correction of her crowding. Review of the medical history revealed no allergies or medical problems. She was in good health and had no contraindications to dental treatment. No signs or symptoms of temporomandibular dysfunction were noted. There was no history of trauma to the mouth, teeth, lips, or jaws. She presented in the late mixed dentition, and complete orthodontic records were obtained.

Diagnosis

Panoramic and cephalometric radiograph analysis (Figure 1a–c) revealed a horizontally impacted mandibular left

^a Mayo Clinic, Consultant, Department of Dental Specialities, Rochester MN

^b Visiting student, UCLA School of Dentistry, Los Angeles, CA

Corresponding author: Joe Rebellato, Mayo Clinic, Department of Dental Specialities, 200 First Street SW, Rochester MN 55905 (e-mail: rebellato.guiseppa@mayo.edu).

Accepted: August 2002. Submitted: August 2001.

© 2003 by The EH Angle Education and Research Foundation, Inc.

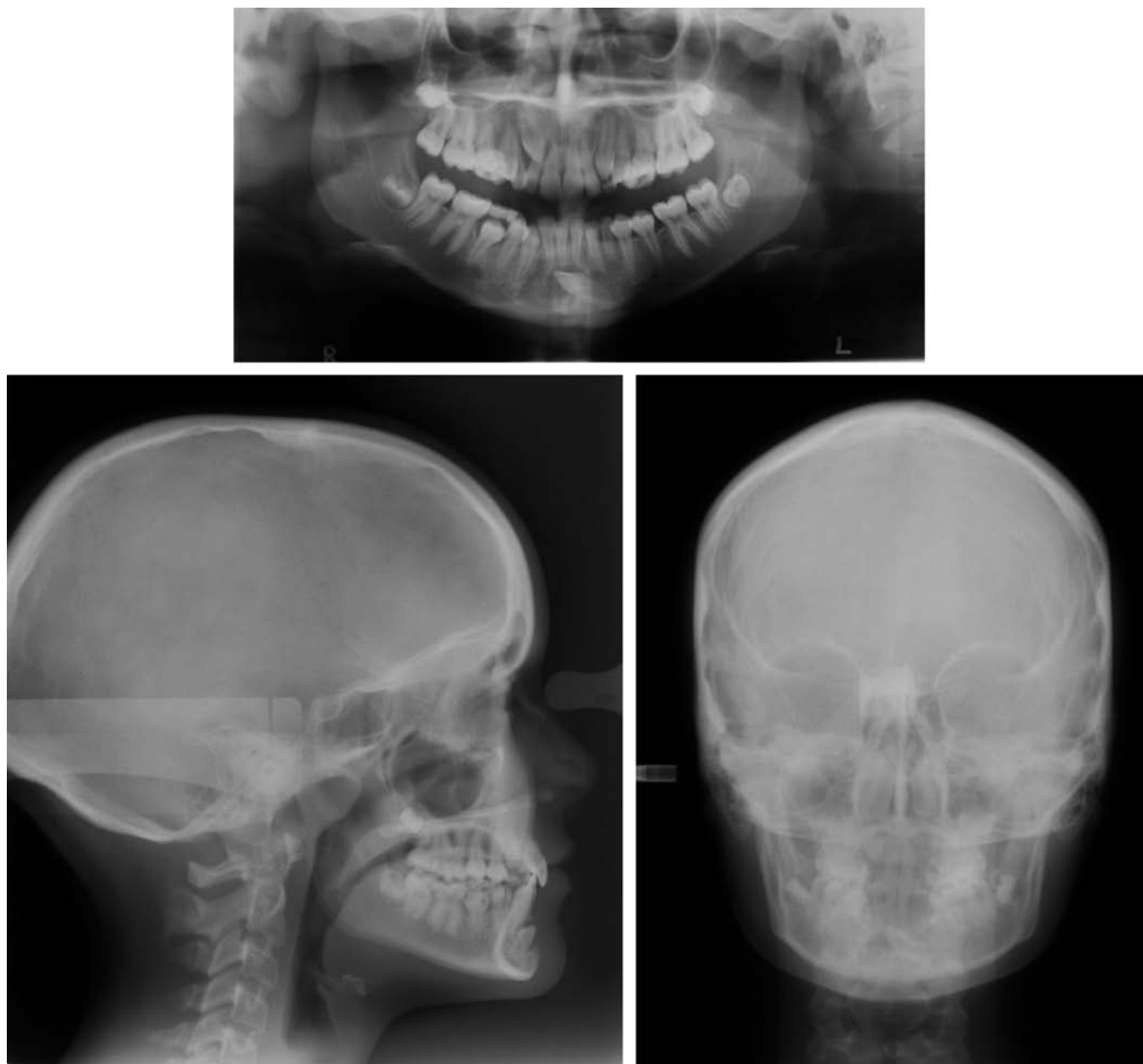

FIGURE 1. (a)–(c) Pretreatment panoramic, lateral cephalometric, and posteroanterior radiographs.

canine with its crown located slightly mesial to the right lateral incisor root apex and an associated eruption cyst. A palatally impacted, ectopically erupting upper right canine was also noted. All permanent teeth were present and developing. The full mouth series revealed no caries or other pathology and many primary teeth about to exfoliate.

Pretreatment facial photographs revealed a straight profile and excessive gingival display (Figure 2a–c). Pretreatment intraoral photographs (Figure 3a–e) and study model analysis (Figure 4a–e) revealed an end on molar relationship bilaterally with mild mandibular and maxillary anterior crowding. The maxillary primary second molars were present and very loose. The dental midlines were coincident.

The patient had a deep bite tendency with an overbite of 60% and associated palatal impingement. A lingual crossbite was noted between tooth #53 (upper right primary canine-FDI numbering system) and tooth #43 (lower right permanent canine) and a buccal crossbite noted between #24 and #34. The mandibular arch was square-tapered and the maxillary arch was ovoid, with arch perimeter deficiencies of 3 and 6 mm, respectively.

Lateral cephalometric analysis (Table 1) revealed a normal skeletal relationship, albeit with slight tendency for mandibular prognathism. Maxillary incisors were upright and mandibular incisors were retroclined resulting in an excessive interincisal angle.



FIGURE 2. (a)–(c) Pretreatment clinical photographs. Note excess gingival display.

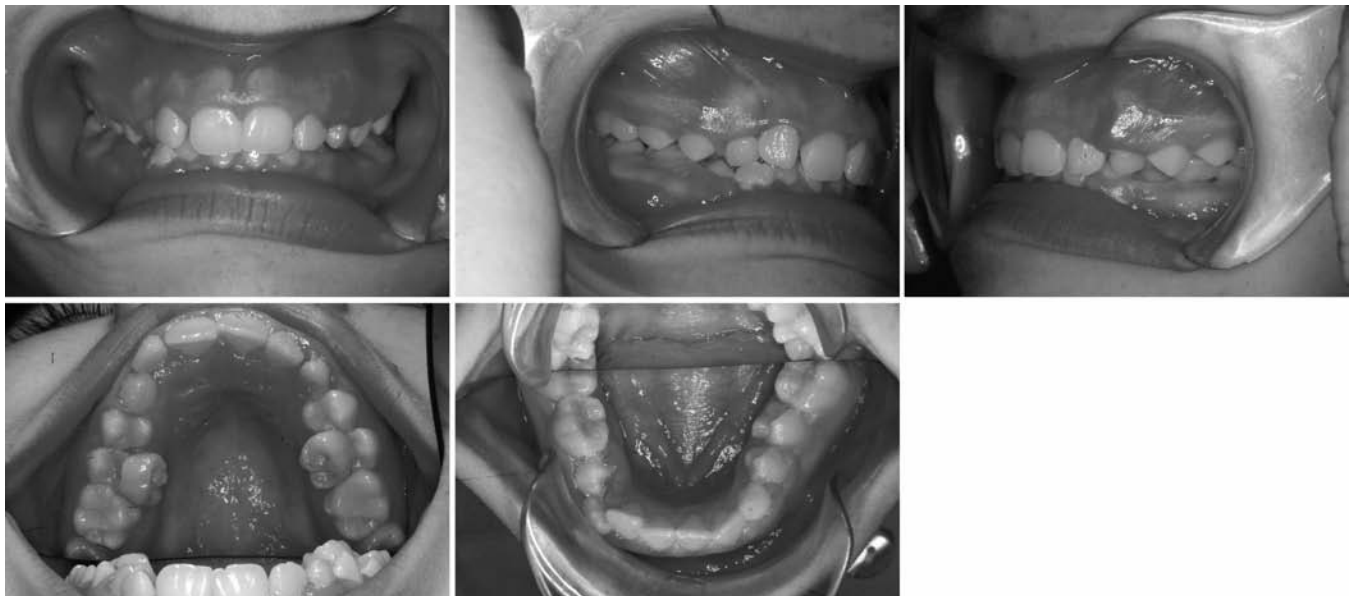


FIGURE 3. (a)–(e) Pretreatment intraoral photographs.

Treatment objectives

The treatment plan included:

1. Surgical removal of the left transmigrated canine and maintenance of the mandibular left primary canine (tooth #73) to preserve alveolar bone height and width, until the patient would be ready for an endosseous implant and crown or other prosthetic replacement.
2. Correction of the palatally impacted right canine by surgical exposure and orthodontic eruption into proper arch position.
3. Correction of the excessive gingival display with gingivectomy and frenectomy.
4. Correct the excessive overbite and interincisal angle, and level and align the dental arches.
5. Establish a bilateral Class I molar relationship with ideal overbite and overjet.
6. Minimally impact the soft tissue profile.

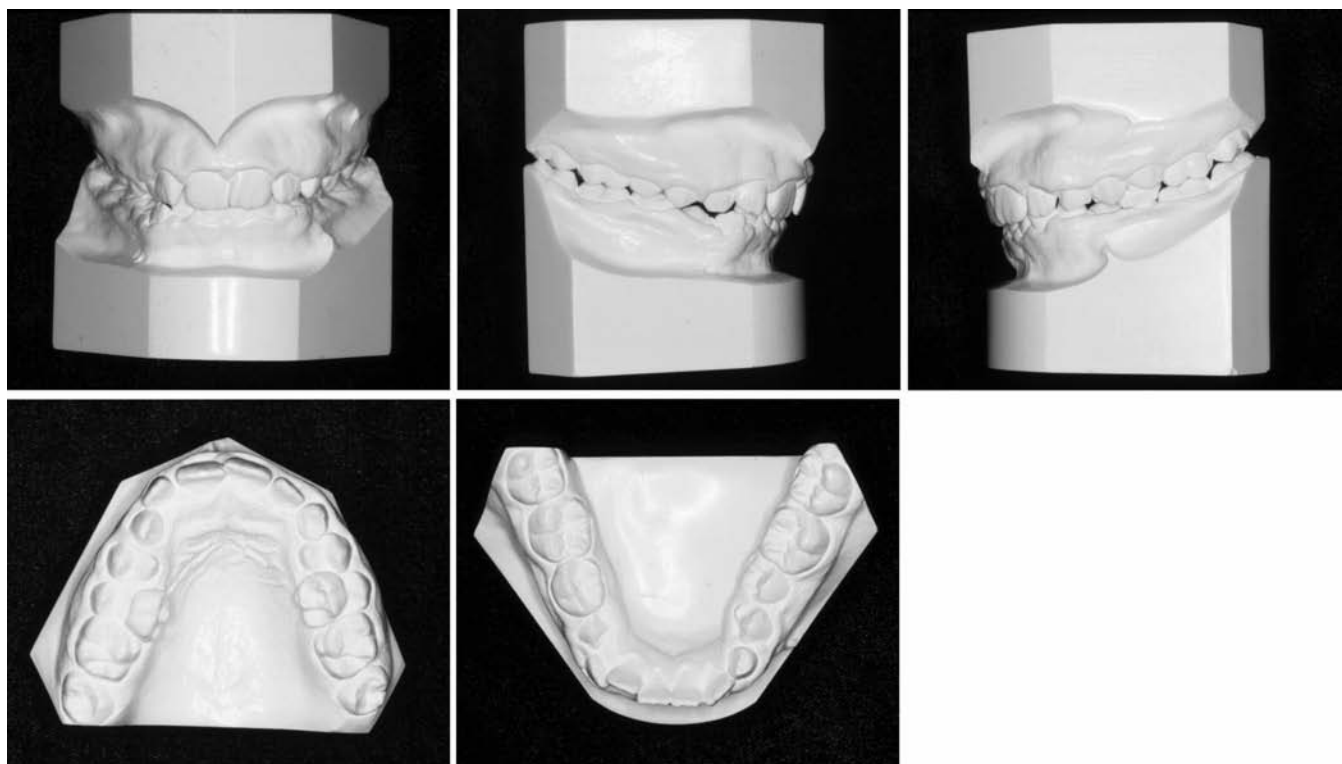


FIGURE 4. Pretreatment study models.

TABLE 1. Cephalometric Measurements

Measurement	Mean	Initial	Final
SNA (°)	81	82.3	81.7
SNB (°)	78	80.9	82.5
ANB (°)	3	1.3	-0.8
Mx length (mm)	80.0	84.5	85.8
Md length (mm)	97.0	113.4	120.6
Wits (mm)	0	-0.6	0.6
SN-GoGn (°)	32	29.3	23.8
y axis (°)	59	58.1	56.3
U1 to NA (°)	24	14.3	30.9
U1 to NA (mm)	4	2.1	6.9
U1 to SN (°)	103	96.6	112.6
L1 to NB (°)	26	21.0	28.2
L1 to NB (mm)	5	0.9	3.7
U1/L1 (°)	125	143.3	121.7
NLA (°)	102	108.4	98.8
Pog to NB (mm)	3	2.0	3.1

Treatment alternatives

If the diagnosis of canine impaction in this patient had been made earlier, it is possible that tooth #33 might have been in a better position for orthodontic eruption into the arch. Another treatment option might have been autotransplantation. However, with a severely impacted tooth, it is very difficult to remove it in one piece. Again, success of this treatment alternative is dependent on the development of the tooth and higher success rates are seen in teeth with incompletely formed root apices. In this case, the mandibular

canine root was completely formed which could have compromised the success of this alternative.

In a patient presenting with a transmigrated mandibular canine and severe arch perimeter deficiency, extraction of the canine along with other teeth could be an option. Although canine guidance would be compromised, Robertson and Mohlin¹¹ found no statistical differences in posterior disclusion during laterotrusive movements in patients with canine substitution of a congenitally missing lateral incisor and space closure moving a premolar into the canine position.

Another alternative might be to leave the transmigrated canine in place; however, this approach can lead to long-term complications. Impacted teeth have the potential to become ankylosed, making surgical removal more difficult. They can also forcefully erupt leading to root resorption of other permanent teeth and crowding. Transmigrated teeth not only can lead to root resorption of overlying roots, but they have also been reported to erupt in their new locations on the contralateral arch.⁶

Treatment progress

The treatment objectives and alternatives were explained to the patient and her mother and informed consent was obtained. An upper 2 × 4 appliance was constructed, and the bracket on tooth #12 (upper right lateral incisor) was rotated 180° to reverse the torque on the tooth. This was done to obtain labial root torque on this tooth, to minimize

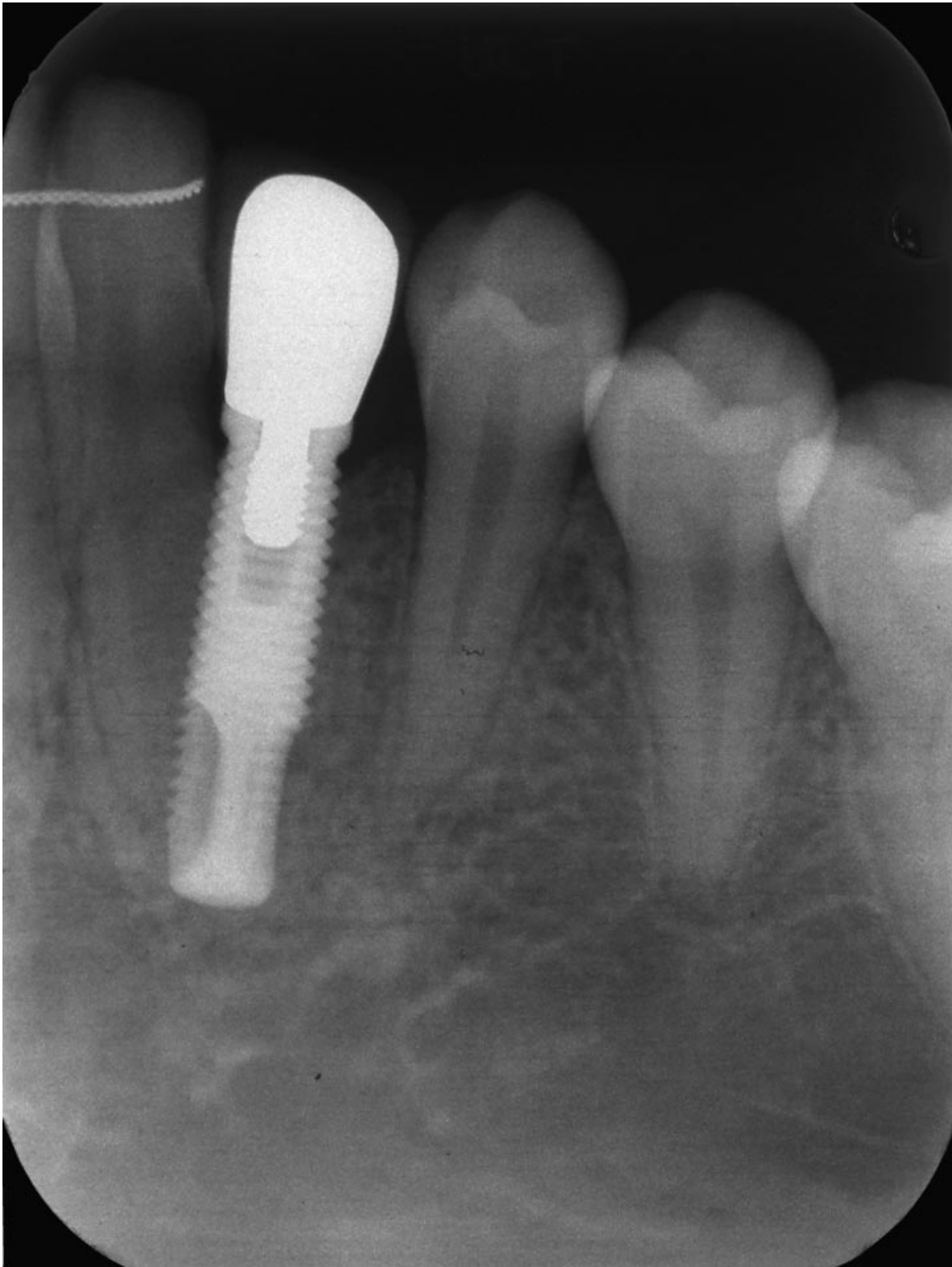


FIGURE 5. Endosseous implant placed at site of extracted mandibular left canine.

the chance of contact between the apex of tooth #12 and the crown of tooth #13.

The patient was referred to an oral surgeon for removal of tooth #33 and soft tissue uncovering of #13. After ade-

quate sedation was established, tooth #33 was exposed through a sulcular incision in the mandibular midline and extracted. Tooth #53 was extracted, and removing palatal tissue with sharp dissection exposed tooth #13. The crown

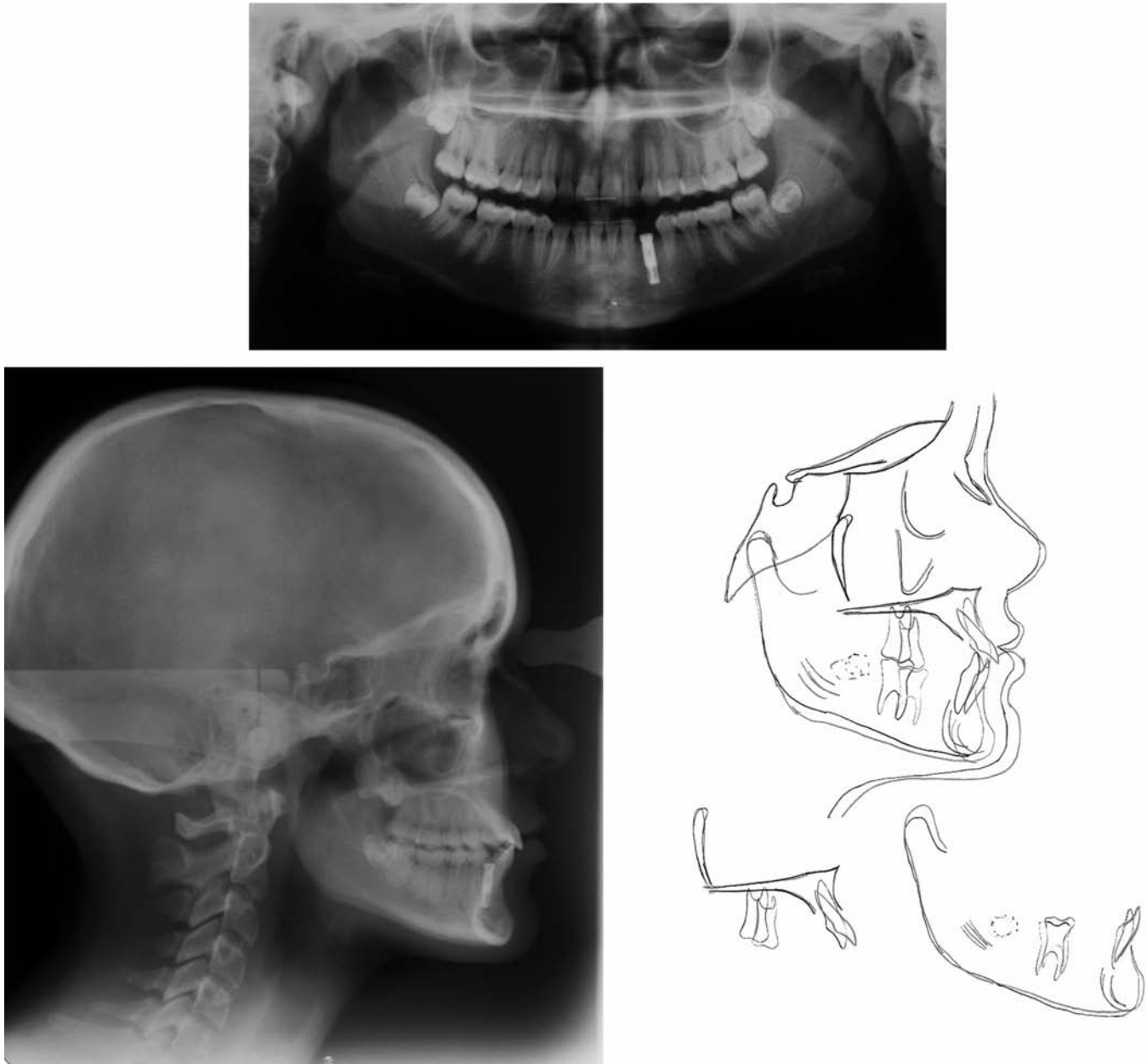


FIGURE 6. (a)–(c) Posttreatment panoramic and lateral cephalometric radiographs, and superimposed cephalometric tracings: initial, 13 years 1 month; final, 15 years 11 months.

was completely exposed, and the wound was left open to heal by secondary intention.

After surgery, the upper arch wire was changed to 0.017 × 0.025 inch TMA, a transpalatal arch was inserted and traction started on #13. Nine months later, the tooth was erupted and appliances were removed to allow for further eruption of the remaining permanent dentition.

Eight months later, full upper and lower appliances were placed. The maxillary wire sequence was 0.016 inch nickel-titanium, 0.016 × 0.022 inch nickel-titanium and low friction 0.017 × 0.025 inch TMA wires. A reverse curve in the upper arch wire was used for reducing the overbite. The

mandibular wire sequence was 0.016 inch nickel-titanium, 0.016 × 0.022 inch nickel-titanium, 0.016 × 0.022 inch stainless steel and a low friction 0.016 × 0.022 inch TMA. An open-coil was added between #32 and #34 to create ideal spacing for the future canine crown, and bends were placed to increase the root divergence of #32 and #34 to facilitate implant placement. This second phase of treatment lasted 16 months.

Before appliance removal, the patient was referred to a periodontist for implant placement, gingivectomy, and frenectomy. Lateral cephalograms, taken before and at the end of phase II of orthodontic treatment, confirmed the patient



FIGURE 7. (a)–(e) Posttreatment clinical photographs.

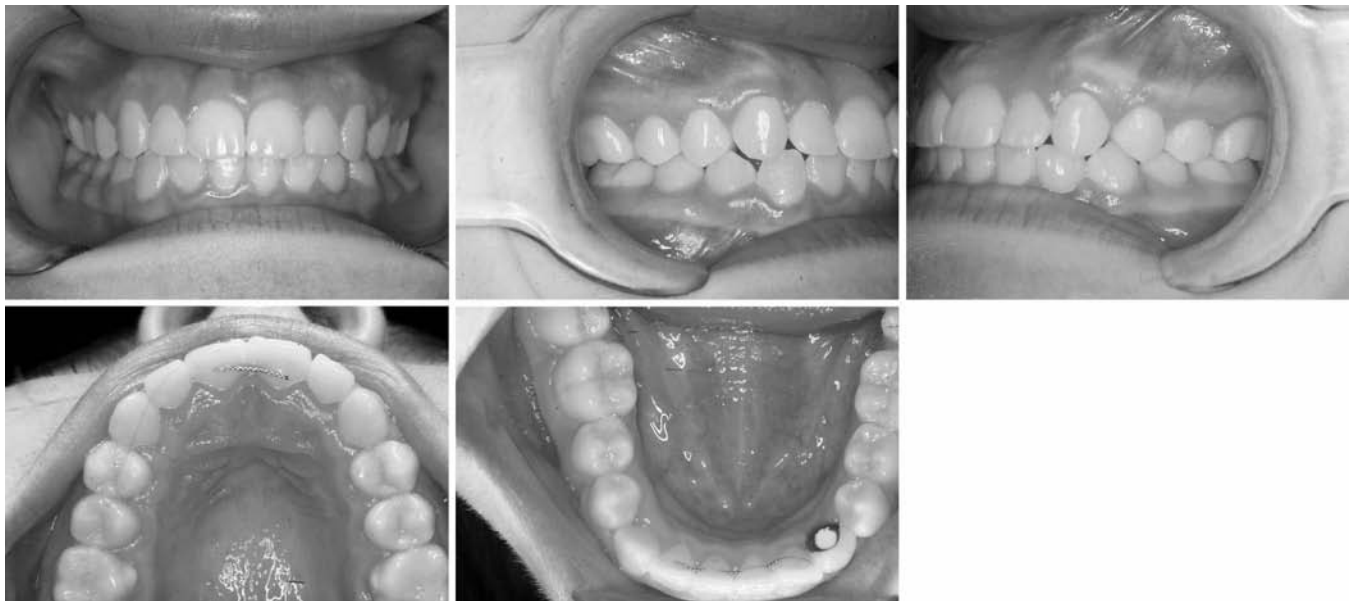

FIGURE 8. (a)–(e) Posttreatment intraoral photographs.

to be skeletally mature and nongrowing. The excessive gingival tissue on the facial surface of teeth #16 to #26 was removed by a gingivectomy technique, and a maxillary frenectomy was also done. Tooth #73 was removed with forceps. Appliances were removed one week after surgery and a 0.0175-inch wire was bonded on the lingual surfaces of the upper central incisors and on all four lower incisors. The next day, upper and lower Hawley retainers (with an

acrylic pontic tooth #33) were inserted. One month later, an endosseous implant (Branemark 4 × 15 mm) was placed at the site of missing tooth #33 (Figure 5). The healing cap was removed three months later, and a 3-mm regular platform-healing abutment was attached. The pontic tooth on the lower Hawley was adjusted to fit. Two months later, an implant crown was inserted by the prosthodontist, and the pontic on the lower Hawley was removed.

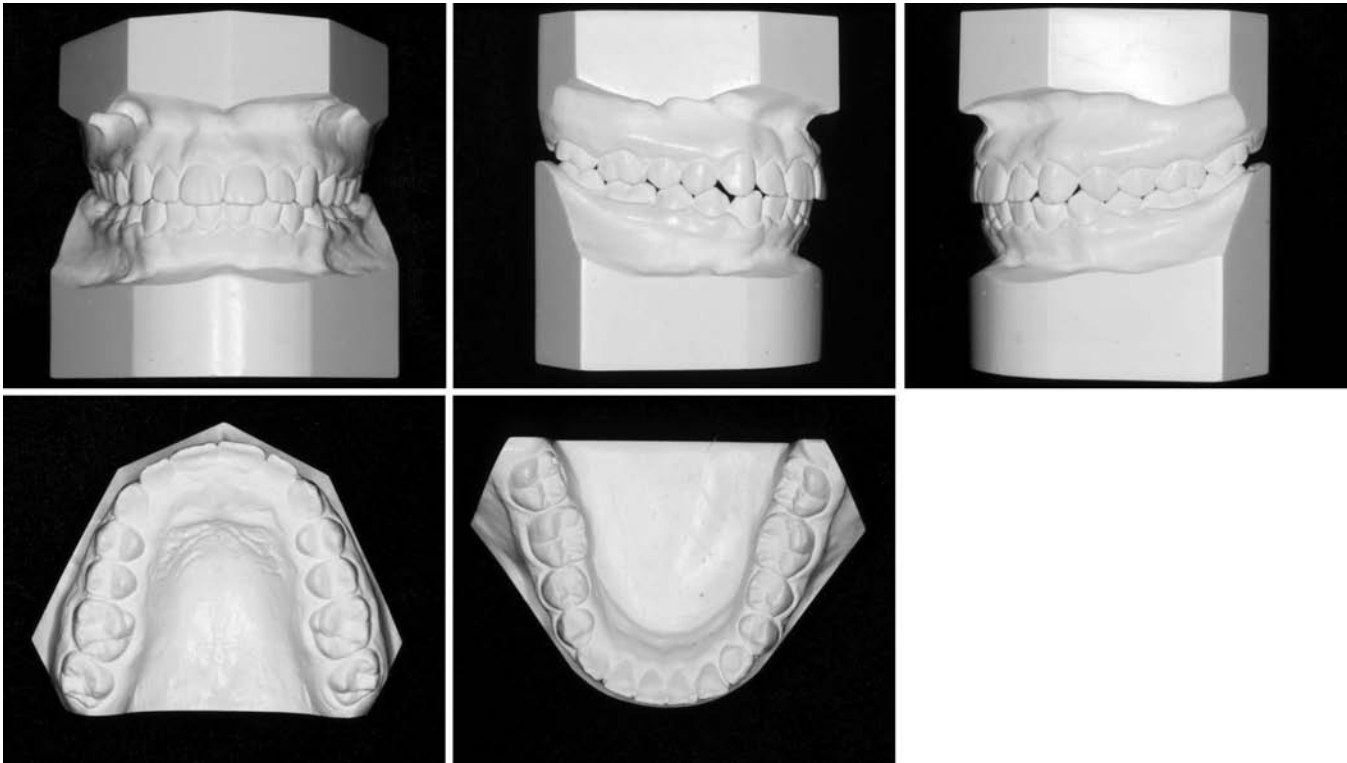


FIGURE 9. (a)–(e) Posttreatment study models.

RESULTS

The treatment plan included several surgical techniques along with the orthodontic treatment to obtain favorable results. Exposure of the palatally impacted right canine and subsequent traction for nine months was successful in allowing tooth #13 to move into its proper arch position. Surgical extraction of the left transmigrated canine was performed uneventfully. By retaining tooth #73 until a month before implant placement, the alveolar bone maintained an ideal height and width for future implant support. The implant achieved osseointegration, and the abutment provided adequate esthetics and function. Gingivectomy and frenectomy techniques reduced the amount of gingival display, creating esthetically pleasing clinical crown lengths in the maxillary arch.

Orthodontic techniques were used to correct the patient to Class I molars and canines bilaterally. The arches were aligned and leveled, and ideal overbite and overjet were established. The relationship of the maxillary and mandibular anterior teeth improved and is evident on the cephalometric analysis. The interincisal angle decreased from 138° to 122° because of proclination of both the maxillary and mandibular teeth (U1 to NA changed from 17.5° to 27° and L1 to NB changed from 23.8° to 28.2°). The dental and minor skeletal changes had minimal effect on the patient's soft tissue profile. The patient was very pleased with the results obtained. Final treatment records and superimposed

initial and final cephalometric tracings are shown in Figures 6–9.

DISCUSSION

Although a transmigrated canine has been reported in a 62-year-old patient¹², treatment considerations for transmigratory teeth depend on the stage of development and distance of migration (or angulation) when they are identified. When the root apices are closed, extraction often is the only choice. Clinical clues that can help diagnose this problem at an early stage to avoid extraction have been presented. A study by Joshi⁶ identified axial inclination criteria that can help predict the likelihood of canine impaction and transmigration. Canines lying within 25° to 30° of the midsagittal plane have a tendency for impaction, but they do not tend to cross the midline. Canines that are found within 30° to 50° of the midsagittal plane tend to cross the midline and for those at an angle greater than 50° , transmigration is almost always the rule.¹³

If these malpositioned teeth can be identified early, it may be possible to orthodontically correct them. Stafne¹⁴ found that the greatest amount of tooth migration occurred before the root is completely formed, which emphasizes the importance of early diagnosis to resolve this problem before the tooth migrates far from its ideal location. When detected early, the tooth can be surgically exposed and moved using orthodontic forces. Autotransplantation is

another approach to correct this problem; however, an immature tooth is required for success, and the difficulty in removing the tooth in one piece complicates the procedure. The only documented report of successful corrections of transmigrated canines using orthodontic treatment was described by Wertz,¹⁵ and his success was limited to labially positioned canines.

The decision on whether to extract these teeth can also be dependent on whether arch perimeter deficiencies exist, which would favor an extraction method of treatment anyway. In this patient, a deep overbite, upright incisors and minimal crowding supported extraction of no further permanent teeth other than the transmigrated canine.

As previously mentioned, heredity can play a role in the development of impacted teeth. Interestingly, the patient's brother presented for an orthodontic consultation and was diagnosed with a palatally impacted maxillary canine.

CONCLUSIONS

Multidisciplinary care involving surgical exposure and traction of a palatally impacted maxillary canine, surgical extraction of a transmigrated mandibular canine with implant replacement and crown, full orthodontic appliance treatment, and cosmetic periodontal procedures in the maxillary arch provided this patient with an excellent esthetic and functional result. The "team" approach used between the orthodontist, periodontist, prosthodontist, and oral surgeon was effective in providing the patient with a result that could not have been achieved by orthodontics alone. "Together, Each Achieves More."

REFERENCES

1. Daskalogiannakis J. *Glossary of Orthodontic Terms*. 1st ed. Berlin, Germany: Quintessence Publishing; 2000:142.
2. Nodine AM. Aberrant teeth, their history, causes and treatment. *Dent Items Interest*. 1943;65:440-451.
3. Kerr WJS. A migratory mandibular canine. *Br J Orthod*. 1982;9:111-112.
4. Rohrer A. Displaced and impacted canines. *Int J Orthod Oral Surg*. 1929;15:1002-1004 [cited by: Javid B. Transmigration of impacted mandibular cuspids. *Int J Oral Surg*. 1985;14:547-549].
5. Thoma KH. *Oral Surgery*. 2nd ed. St. Louis, Mo: CV Mosby; 1952.
6. Joshi MR. Transmigrant mandibular canines: a record of 28 cases and a retrospective review of the literature. *Angle Orthod*. 2001;71:12-22.
7. Ando S, Aizawa K, Nakashima T, Sanka Y, Shimbo K, Kiyokawa K. Transmigration process of the impacted mandibular cuspid. *J Nihon Univ Sch Dent*. 1964;6:66-71.
8. Bruszt P. Neurological anomaly associated with extreme malposition of a mandibular canine. *Oral Surg Oral Med Oral Pathol*. 1958;11:89-90.
9. Joshi MR, Bhatt NA. Canine transposition. *Oral Surg Oral Med Oral Pathol*. 1971;31:49-53.
10. Vichi M, Franchi L, Bassarelli V. Contributo clinico sulla tras-migrazione del canino inferiore permanente. *Minerva Stomatol*. 1991;40:579-589, and the Transmigration of the Mandibular Permanent Canine. Poster presented at: 68th EOS Congress; June 1992; Venice-Lido, Italy.
11. Robertsson S, Mohlin B. The congenitally missing upper lateral incisor. A retrospective study of orthodontic space closure versus restorative treatment. *Euro J Orthod*. 2000;22:697-710.
12. Abbot DM, Svirasky JA, Yarbrough BH. Malposition of the permanent mandibular canine. *Oral Surg Oral Med Oral Pathol*. 1980;49:97.
13. Pratt RJ. Migration of canine across the mandibular mid-line. *Br Dent J*. 1969;126:463-464.
14. Stafne EC. Malposed mandibular canine. *Oral Surg Oral Med Oral Pathol*. 1963;16:1330.
15. Wertz RA. Transmigrated mandibular canines. *Am J Orthod Dentofacial Orthop*. 1994;106:419-427.